MICROVASCULAR RESEARCH, 3, 354–360 (1971)

"In Vivo" Microscopic Study of the Response of the Hepatic Microvascular System to Carbon Tetrachloride Poisoning[1]

SAMUEL G. MCCLUGAGE, JR,[2] AND ROBERT S. MCCUSKEY[3]

Department of Anatomy, University of Cincinnati College of Medicine, Cincinnati, Ohio 45219

Received March 15, 1971

The initial effect of carbon tetrachloride poisoning on the microvascular system and parenchyma of the rat liver was studied using an *in vivo* microscopic method. The results suggest that the initial lesion is in the microvascular compartment; this reaction institutes an inflammatory response characterized by adhesion of white blood cells to the endothelium of sinusoids and central venules, and subsequent diapedesis of white blood cells. Carbon tetrachloride later induces alterations in the parenchyma resulting in fatty changes, hydropic degeneration, and necrosis in a stepwise manner. The combined events, microvascular and parenchymal, produce marked alterations of hepatic blood flow thus promoting anoxia and pathologic lesions.

INTRODUCTION

The pathogenesis of carbon tetrachloride-induced cirrhosis is in some dispute. Aterman (1) described cirrhosis induced by carbon tetrachloride as a chronic inflammatory process that produces alterations in the vascular and parenchymal components of the liver. Contributing features cited have included fatty changes, necrosis, and congested sinusoids (10–12). Petrelli and Stenger have suggested that the wall of the sinusoid might be the initial site of damage by carbon tetrachloride (9). On the other hand, Hase (3), using silicone rubber perfusions, studied the effects of carbon tetrachloride on the "microcirculation" (3) of livers in rats. He concluded that the microvascular lesions always followed the parenchymal lesions. Other investigators (14, 15), studying liver microscopically, reported the response of the exposed, intact liver to this hepatotoxin. Only limited observations could be made in these *in vivo* studies (14, 15) since relatively low magnifications were used with resulting poor resolution, thus prohibiting accurate evaluation of cellular detail. No work has been reported using *in vivo* microscopic methods that permit observations of cellular detail at the limit of resolution of the light microscope (4,5). Thus, the present study was designed to examine concomitantly the hepatic microvasculature and parenchyma in the living state in order to elucidate further the events that antecede cirrhosis.

[1] Presented in part in motion picture form at the Midwestern Association of Anatomists Meeting, Omaha, Nebraska, November 15, 1969.

[2] Present address. Department of Anatomy, Louisiana State University Medical Center, 1542 Tulane Avenue, New Orleans, Louisiana 70112.

[3] Recipient of N.I.H. Research Career Development Award, AM-42,370.

10035423 12

Source: https://www.industrydocuments.ucsf.edu/docs/qrvm0000

MATERIALS AND METHODS

One-hundred and fifty male Sprague–Dawley rats (100–125 g) were used. Rats in groups of 25 were injected intraperitoneally or subcutaneously with 0.15 cc CCl_4 (carbon tetrachloride) mixed with 0.15 cc of mineral oil every other day for a period of 2 weeks. Control animals were given placebos of mineral oil or of Ringer's solution. The animals were fed a standard laboratory diet and were given water *ad libitum* throughout the course of the experiment.

An *in vivo* method reported by McCuskey (4,5) was used to study the liver. Animals were anesthetized by intraperitoneal injection of 20% ethyl carbamate (Urethan, 1.5 g/kg). After laparotomy a lobe of the liver was exteriorized by floating it onto a window of Saran Wrap (Dow Chemical, Midland, Michigan) which overlayed a substage condenser. Homeostasis was maintained by irrigating the surface of the liver with Ringer's solution warmed to body temperature (4,5). Transillumination of the exposed edge of the liver was accomplished with monochromatic light (390–650 mμ) brought to the liver by the substage condenser of a modified Leitz Panphot microscope. Observations were made by direct microscopy at magnifications of 100–1000× using Leitz water-immersion objectives (10, 22, 50, and 80 ×) with appropriate oculars, or the optical images were projected onto the photocathode of a RCA vidicon (PK-301) or image orthicon television system (TK-31A) and kinérecorded with a modified Arriflex-16S, 16-mm motion picture camera. Kodak 16-mm Tri-X reversal film was used (4,5). During the 2-week treatment period, the liver was examined immediately after CCl_4 administration and at intervals up to 2 weeks.

Routine histological frozen and paraffin sections were prepared from the liver from some of the animals in order to correlate the *in vivo* microscopic observations with fixed tissue sections; these were stained with oil red O or hematoxylin and eosin.

RESULTS

The structure of the liver was altered progressively during the 2-week period of treatment with CCl_4. Treatment and observations could not be extended past 2 weeks since the CCl_4 induced widespread necrosis, shrinkage, and thickening of the liver preventing adequate definition of the histology of the organ *in situ*.

Carbon tetrachloride had its first visible effect on the microvasculature within 2 hr. This effect became progressively more severe during the first 2 days of treatment. In the majority of the livers observed during this period, the endothelium of the sinusoids became thickened and white blood cells adhered to the walls of the sinusoids in the centrolobular portions of the lobules (Fig. 1). Small aggregates of leukocytes also were observed to adhere to the endothelial wall of central venules. In the healthy animal with optimal circulation, white blood cells were never observed to adhere to the endothelium in this manner (Fig. 2). this diffuse sticking and aggregation resulted in stasis and congestion in the sinusoids, and led to an apparent reduction in the linear velocity of blood flow in the central venules as compared with observations made in control animals. Many of these white cells also passed through the endothelium of the central venules and sinusoids and entered the extravascular space. Subsequently, in many

1003542313

Source: https://www.industrydocuments.ucsf.edu/docs/qrvm0000



FIG. 1. Aggregation and adhesion of white blood cells (arrows) to endothelium (E) of sinusoid 2 hr after administration of CCl_4. Single frame from motion picture. Size marker is 5 μ.

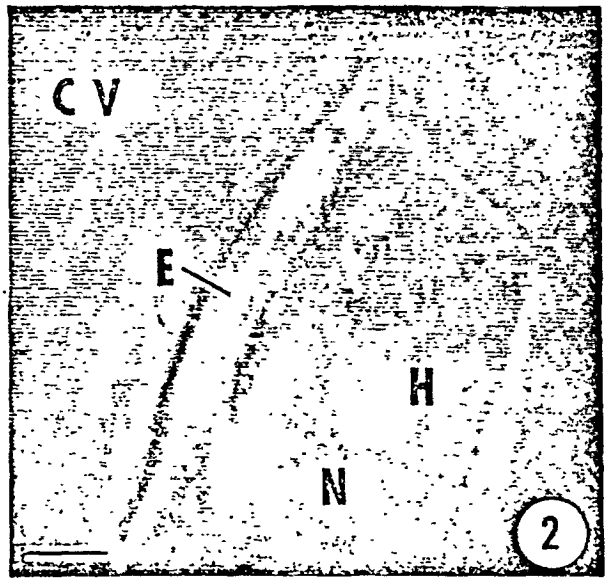

FIG. 2. Central venule (CV) with optimal circulation in nontreated, healthy liver. Note that there are no white blood cells adhering to the endothelium (E); N, nucleus of hepatic cell (H). Single frame from motion picture. Size marker is 5 μ.

1003542314

Source: https://www.industrydocuments.ucsf.edu/docs/qrvm0000

lobules red blood cells extravasated through the endothelium of the sinusoids and central venules resulting in minute hemorrhages. Toward the end of the treatment period, central venules were obscured by centrolobular necrosis, hemorrhage, and moderate fibrosis.

While these changes produced marked alteration of blood flow, not all vascular channels were affected; some vessels and lobules were relatively normal in appearance. The lesions described were always most severe in the centrolobular areas while the portal areas of the same lobules were normal in appearance, exhibiting little vascular involvement.



FIG. 3. Hepatocytes with perinuclear granulation (G), N, nucleus; CV, central venule. Five days after initial administration of CCl_4. Single frame from motion picture. Size marker is 5 μ.

Visible parenchymal alterations followed the microvascular response. During the first 4 days of exposure to CCl_4, small fat vacuoles developed in hepatocytes extending from the midlobular region to the central venules. These vacuoles displaced the nuclei to the periphery of the cell. Cells in the periportal areas exhibited no detectable fatty change.

During the intermediate stage of treatment, 5–9 days, fat accumulation became more severe but remained predominantly in the centrolobular region. Cells now contained multiple vacuoles; others exhibited perinuclear granulation, especially cells adjacent to central venules (Fig. 3). Fibrosis became evident in a few necrotic centrolobular areas.

In the later stages, 10–14 days, in addition to the above changes, large hypertrophied hepatocytes were evident in centrolobular and midlobular areas. The hepatocytes contained a mass of perinuclear granules surrounded by a homogeneous cytoplasmic matrix; this effect was a progressive development from the parenchymal changes

1003542315

Source: https://www.industrydocuments.ucsf.edu/docs/qrvm0000

described in the intermediate stage. At this time hepatocytes in the periportal areas of many lobules had undergone some fatty change while the centrolobular areas of these same lobules were necrotic.

Throughout the course of the experiment, increasing deposits of fat, debris, and hemorrhage beneath the capsule made visualization difficult and at times impossible.

Frozen and paraffin sections confirmed the lesions observed *in vivo* in the microvascular and parenchymal compartments.

DISCUSSION

The hepatotoxicity of CCl_4 has been the subject of many investigations. The variability of results may be attributed to the different dosages of CCl_4 used, the different routes of administration, and the age and sex of the animal since all of these factors are known to affect the hepatotoxicity of CCl_4 (13). By using low doses of CCl_4 in conjunction with a short time sequence (2 weeks), it was possible to study in the living state some of the initial effects of CCl_4 upon the rat liver. The histologic alterations induced by CCl_4 and observed sequentially *in vivo* were the following: (a) endothelial damage with adhesion of white cells to the walls of sinusoids and central venules; (b) reduced blood flow through sinusoids and central venules as compared with control animals due to plugging of these vessels by adherent white blood cell masses; (c) diapedesis of white cells into the extravascular compartment; (d) fatty metamorphosis and hydropic degeneration of parenchymal cells, centrolobular necrosis, and hemorrhage; (e) further reduction of blood flow through sinusoids as a result of impingement of hypertrophied hepatocytes on the sinusoids; and (f) widespread vascular congestion and necrosis. These results suggested that the primary site of injury of the CCl_4-poisoned rat liver might be in the microvascular system.

The alterations described above are not unexpected since CCl_4-induced cirrhosis has been classified as a chronic inflammatory condition (1). The results of this study are in agreement with the findings of Zweifach *et al.* (16) who studied how damaged endothelium alters the behavior of white cells during an inflammatory response. The adhesion and aggregation of white blood cells to endothelium may be a cause of tissue anoxia by greatly reducing blood flow through the microvascular system of the liver. Plugging of sinusoids and central venules by leukocytes, diapedesis of white blood cells, and hemorrhage reflect endothelial damage (16). Apparently this damage is initially induced by the CCl_4, and later augmented by anoxia due to a decreased blood flow through the sinusoids. Petrelli and Stenger (9) were able to reduce the hepatotoxic effects of CCl_4 by giving trypan blue prior to the CCl_4. The trypan blue increased the cytoplasmic mass of the lining cells of the sinusoid, thus reducing the accessibility of the extravascular compartment to CCl_4. This suggests, as does this report, that the initial lesion is in the microvascular compartment. In addition, subsequent swelling of parenchymal cells further reduced blood flow. Since the centrolobular areas are farthest from the oxygenated blood supply, they would be affected first by the anoxia (4,6); the most severe parenchymal lesion was always in the centrolobular region.

Rice *et al.* (10) thought that the initial lesion in CCl_4 hepatotoxicity was not vascular. They believed that blood flow played a minor role in furthering the damage once the parenchymal lesion had been induced. However, an increasing biphasic resistance to

1003542316

Source: https://www.industrydocuments.ucsf.edu/docs/qrvm0000

flow in perfused livers, described by Rice and Plaa (11), could well have been caused by vascular lesions such as we observed rather than by obstruction from increased cellular triglyceride content in the early phase or later necrosis. Nakata and Higaki (7) reported that the hemodynamic changes always followed the appearance of parenchymal lesions in their perfused liver preparations. It would be of considerable interest to determine if the intravascular hemodynamic changes observed *in vivo*, i.e., adhesion and aggregation of white blood cells, can be induced in an organ which is perfused. Although the vascular lesions described in this report were not observed in other *in vivo* studies (14,15), this may be due to differences in methodology, especially the use of high magnifications in this work as opposed to low magnifications and poor resolution.

Although the process of fixation probably washed out many of the adherent white blood cells, tissue sections from this experiment did suggest areas of white cell adhesion and diapedesis through the walls of sinusoids and central venules. Some of the white cells within the vessels were enmeshed in a fibrin matrix.

The parenchymal changes observed *in situ* after CCl_4 poisoning follow conditions described by Gall (2) in cases of nutritional cirrhosis, namely, hepatocyte disintegration, focal necrosis, and a variety of cytoplasmic changes. Pseudolobule formation and fibrous interconnections were lacking probably because of the relatively low dosage of CCl_4 and the short treatment period. For the most part, hepatic architecture was maintained, but widespread centrolobular necrosis occurred in the later stages of treatment.

During the 2-week sequence of treatment, the hepatocytes appeared to undergo three progressive stages of morphologic alteration, i.e., fatty change, hydropic degeneration, advanced hydropic degeneration, and necrosis. In any one stage of parenchymal change the most advanced lesions were always nearest central venules. Thus in the final stage of treatment, at 10–14 days, the parenchymal lesions from within the center of the lobule outward to the periphery, mimicked the CCl_4-induced alterations described by other investigators using light microscopy, namely, necrosis, hydropic degeneration, and fatty changes. The most severe change was always farthest from the oxygenated blood supply (4,6)

The distribution of lesions observed *in vivo* as areas of fatty change, hydropic degeneration (balloon cells) (8), and necrosis was confirmed by the use of frozen tissue sections stained with oil red O.

REFERENCES

1. ATERMAN, L. (1954). Studies in fibrosis of the liver induced by carbon tetrachloride. *Arch. Pathol.* **57**, 1.
2. GALL E. A. (1960). Posthepatitic, postnecrotic, and nutritional cirrhosis. A pathologic analysis. *Amer. J. Pathol.* 36, 241.
3. HASE, T. (1966). Hepatic microcirculatory changes in acute and chronic carbon tetrachloride poisoning in rats. *Amer. J. Pathol.* 49, 1069.
4. MCCUSKEY, R. S. (1966). A dynamic and static study of hepatic arterioles and hepatic sphincters. *Amer. J. Anat.* 119, 455.
5. MCCUSKEY, R. S. (1968). Dynamic microscopic anatomy of the fetal liver. III. Erythropoiesis. *Anat. Rec.* 161, 267.
6. MOSKOW, H. A., PENNINGTON, R C , AND KNISLEY, M. H (1968). Alcohol, sludge, and hypoxic areas of nervous system, liver and heart. *Microvasc. Res.* 1, 174.
7. NAKATA, K., AND HIGAKI, K (1969). Relationship between circulatory disturbance and histological lesions in the isolated rat liver resulting from CCl_4 poisoning. *Microvasc. Res.* 1, 379.

1003542317

Source: https://www.industrydocuments.ucsf.edu/docs/qrvm0000

8. OBERLING, C., AND ROUILLER, CH. (1956). Les effets de l'intoxication aiguë au tétrachlorure de carbone sur le foie de rat. Etude au microscope electronique. *Ann. Anat. Pathol.* 1, 401.
9. PETRELLI, M., AND STENGER, R. J. (1969). The effect of trypan blue on the hepatotoxicity of carbon tetrachloride in the rat. *Exp. Mol. Pathol.* 10, 115.
10. RICE, A. J., ROBERT, R. J., AND PLAA, G. L. (1967). The effect of carbon tetrachloride, administered *in vivo*, on the hemodynamics of the isolated perfused rat liver. *Toxicol. Appl. Pharmacol.* 11, 422.
11. RICE, A. J., AND PLAA, G. L. (1968). Effect of hypophysectomy and spinal cord transection on carbon tetrachloride-induced changes in the hemodynamics of the isolated perfused rat liver. *Toxicol. Appl Pharmacol.* 12, 194.
12. RICE, A. J., AND PLAA, G. L. (1969). The role of triglyceride accumulation and/or necrosis in the hemodynamic responses of the isolated perfused rat liver after administration of carbon tetrachloride. *Toxicol. Appl. Pharmacol.* 14, 151.
13. ROUILLER, Ch. (1964). Experimental toxic injury of the liver. *In* "The Liver," Vol. II. Academic Press, New York.
14. SENEVIRATNE, R. D. (1949). Physiological and pathological responses in the blood vessels of the liver. *Quart. J. Exp. Physiol.* 35, 77.
15. WAKIM, K. G., AND MANN, F. C. (1942). Effect of experimental cirrhosis on the intrahepatic circulation of blood in the intact animal. *Arch. Pathol.* 33, 198.
16. ZWEIFACH, B. W., GRANT, L., AND MCCLUSKEY, R. T. (1965). The sticking and emigration of white blood cells in inflammation. *In* "The Inflammatory Process." Academic Press, New York.

10035423 18

Source: https://www.industrydocuments.ucsf.edu/docs/qrvm0000